



Dr Diana
Yudina
MD
Aesthetic Medicine
Russia

15% TCA MEDICAL PEELING COMBINED WITH COLLAGEN INJECTIONS TO TREAT POST-ACNE SCARS

INTRODUCTION

Post-acne scars may cause has repercussions on the behavior psyche on female patients.

The aim of the present study is to evaluate the efficiency, safety, and revised 3 phases new of post-acne treatment.

MATERIAL & METHOD

1

PHASE 1:

Topical anesthesia 20 min. Skin disinfection. Dermal dissection of subcision depressed scars by using needle 27G in 4 different directions.

2

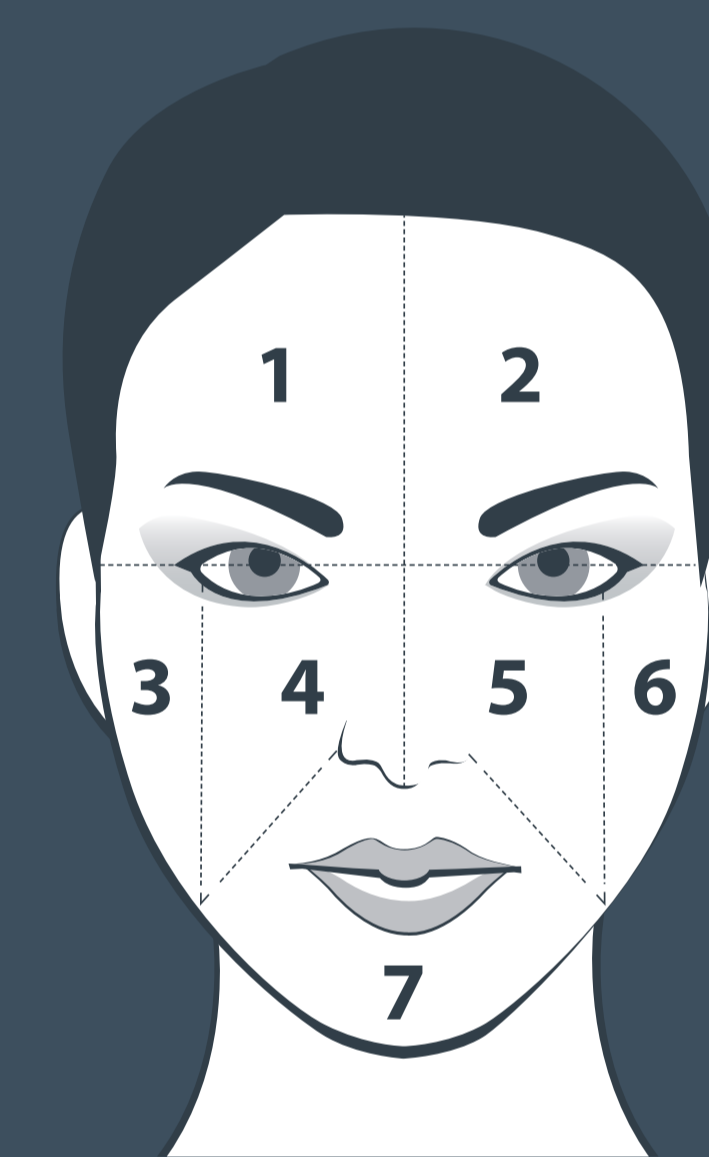
PHASE 2:

Dermal injection of collagen 7% sterile gel with visible hyper correction on the bottom of the depressed scars. Average volume of single injection was 0,1 mL. Total 1 mL per treatment.

3

PHASE 3:

Application of 15% TCA peeling (Easy TCA Classic, Skin Tech) until Grenz Zone followed by post peel protective mask.



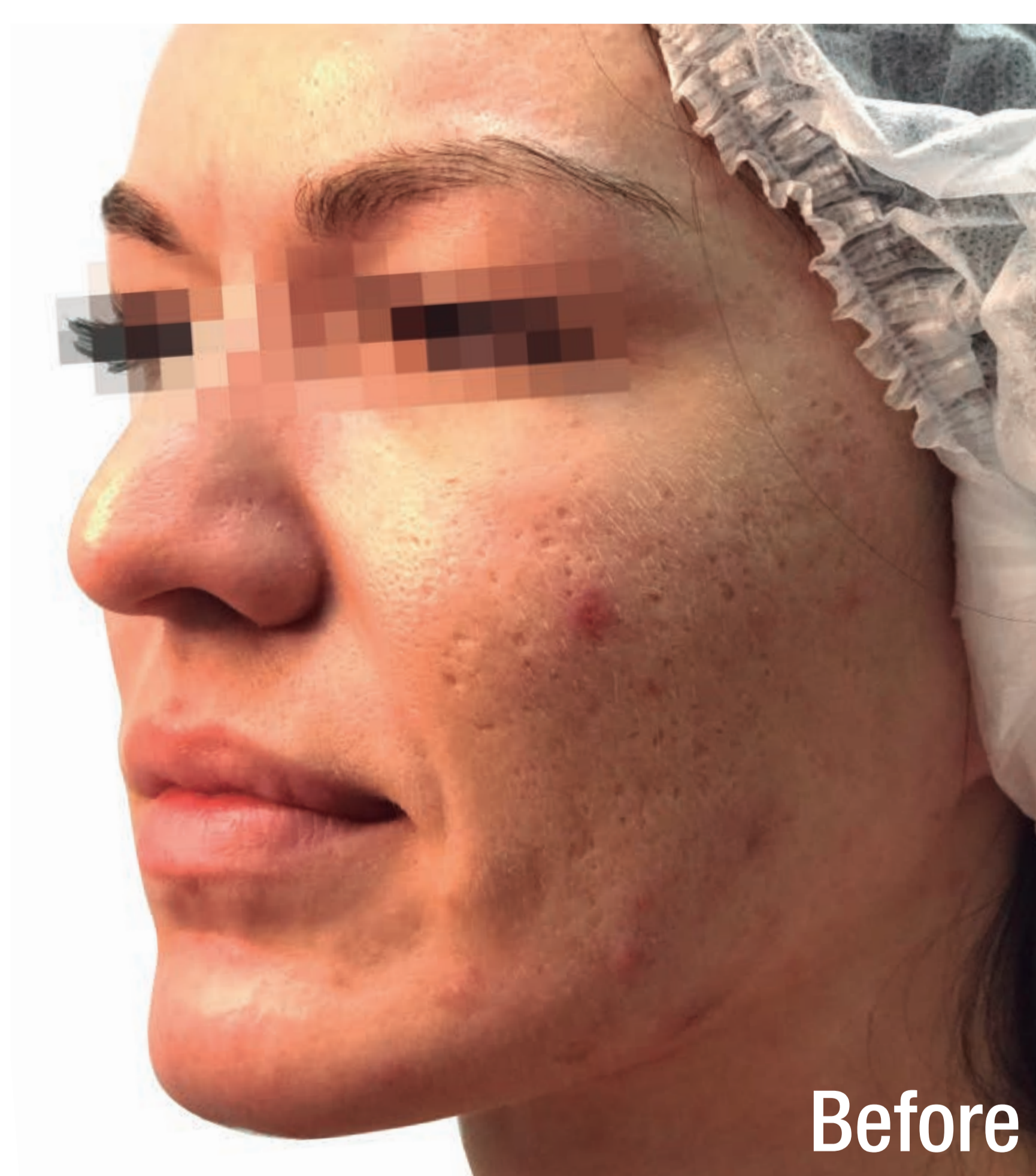RESULTS

26 Female patients

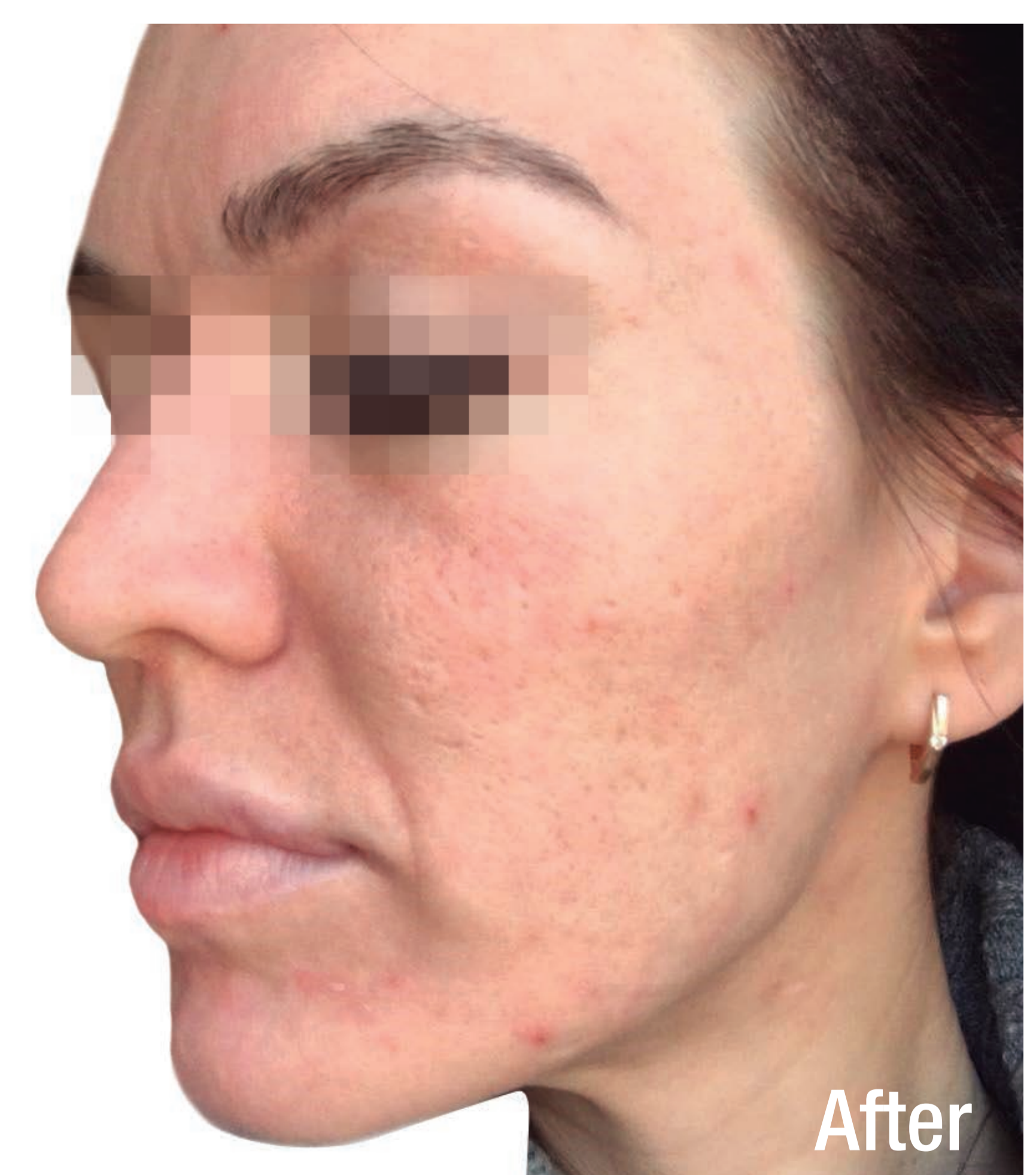with depressed acne scars in period of 2016-2017 received single treatment.

80% of the patients

were highly satisfied with results, retrospectively they ask to repeat the same treatment after 8 months.



Before



After

CONCLUSION

Developed treatment combined dermal dissection, collagen injection and 15% TCA peeling (Easy TCA Classic, Skin Tech) improved appearance of skin, reduced acne scars, improved skin elasticity and skin tone. Single treatment could be recommended in cases of depressed acne scars with long-lasting effect.